

# Complete objective response of neuroblastoma to biological treatment

Giuseppe Di Bella, Biagio Colori

Fondazione Di Bella, Bologna, Italy

“Rizzoli” Institute, Scientific Research and Care Institute, Bologna, Italy;

Correspondence to: Giuseppe Di Bella, MD.,  
“Rizzoli” Institute, Scientific Research and Care Institute  
Via Marconi N°51, Post code 40122, Bologna, Italy  
TEL.: 051 239662; 051 230369; E-MAIL: posta@giuseppedibella.it

Submitted: 2009-05-21 Accepted: 2009-06-09 Published online: 2009-10-04

Key words: **neuroblastoma; remission induction; biological treatment; MDB; melatonin; somatostatin; retinoid; vitamin D3**

Neuroendocrinol Lett 2009;30(4): 1-000 PMID: ----- NEL300409--- © 2009 Neuroendocrinology Letters • www.nel.edu

## Abstract

**OBJECTIVES:** The combined use (MDB) of Somatostatin, Melatonin, Retinoids, Vitamins E, C, and D<sub>3</sub>, with Calcium, Chondroitin sulfate, and microdoses of Cyclophosphamide in a seven-month old baby affected by a voluminous retroperitoneal neuroblastoma measuring 4x8 cm produced a 50% objective response in six months, an almost total response in one year and a complete response at 14 months, with cure and absence of disease for over ten years. **RESULTS:** This paper discusses the rationale and the molecular mechanisms of action of the treatment which has a differentiating, apoptotic and antiproliferative effect, preserving and enhancing both the trophism and functionality of organs and tissues, and the neuroimmunoendocrine and antitlastic homeostasis. This result is in agreement with the positive results already published on the use of the MDB in lymphoproliferative diseases, in stage III and IV lung cancer, in breast cancer and in cancers of the upper aerodigestive epithelia. Without the need for hospitalisation and with no toxicity, the MDB rapidly reduced and then eliminated the voluminous tumoral mass, allowing a normal quality of life and a perfectly normal psychophysical development. **CONCLUSIONS:** We believe it is of use to report this case in order to invite greater interest in the oncological possibilities offered by the immunoneuroendocrine and biological-receptorial properties of the MDB treatment. The purpose of the work was to evaluate the importance of the cytokines, IL-6, IL-8, and TNF- $\alpha$ , and the adhesive molecule, sICAM-1, as risk factors for early-onset neonatal sepsis and intra-amniotic infections.

## Abbreviations :

ATRA - All Trans Retinoic Acid  
BDNF - Brain Derived Neurotrophic Factor  
CCK - Cholecystokinin  
MDB - Di Bella Method  
EGF - Epidermal Growth Factor  
EGFR - Epidermal Growth Factor Receptor  
FGF - Fibroblastic Growth Factor  
GH - Growth Hormone  
GHR - Growth Hormone Receptor  
HGF - Hepatocyte Growth Factor  
IGF 1-2 - Insulin-like Growth Factor 1-2  
IGFR - Insulin-like Growth Factor Receptor  
INSS - International Neuroblastoma Staging System  
MRI - Magnetic Resonance Imaging

MLT - Melatonin  
NBL - Neuroblastoma  
NGF - Nerve Growth Factor  
NT - Neurotrophin  
NHL - Non-Hodgkin's Lymphoma  
PDGF - Platelet-Derived Growth Factor  
PET - Positron Emission Tomography  
RC - Complete objective response  
SST - Somatostatin  
SSTR - Somatostatin Receptor  
TRK - Tyrosine-kinase  
TGF - Transforming Growth Factor  
VEGF - Vascular Endothelial Growth Factor  
VIP - Vasoactive Intestinal Peptide

## INTRODUCTION

We present a case of complete remission with biological therapy (MDB) of an unoperable voluminous retroperitoneal neuroblastoma (NBL) in a seven-month old baby. The case has been monitored since 1998. We report the components of the biological therapy (MDB), together with the results of the blood tests and instrumental examinations performed before and after the treatment.

A brief summary is provided of the rationale of the MDB, the scientific bases, the molecular mechanisms of action and the clinical response, with the patient in complete remission for over 10 years.

## BRIEF NOTES ON NEUROBLASTOMA

NBL originates from cells of the neural crest, affecting the nerve cells of the sympathetic ganglia and is considered to be hereditary.

It is the most common solid extracranial tumour in children, representing 6–10% of all tumours in infancy with an incidence of 7–13 new cases annually/1,000,000 (children < 15 years).

Neuroblastoma has an extremely variable clinical presentation and biological behaviour. The risk evaluation system drawn up by the *Children's Oncology Group* considers not only histological and histochemical data but also the age of the patient, the volume of the tumour mass and the stage according to INSS criteria (*International Neuroblastoma Staging System*):

<b>Stage 1</b>	Unilateral or midline tumour confined to the area of origin, removed completely with negative or metastatic lymph nodes removed together with the tumour.
<b>Stage 2A</b>	Unilateral or midline tumour, mostly removed but not radically and with negative lymph nodes
<b>Stage 2B</b>	Unilateral or midline tumour, radically removed but with positive lymph nodes
<b>Stage 3</b>	Tumour crossing the midline, infiltrating the surrounding tissues ± regional lymph nodes Tumour that does not cross the midline but with positive contralateral lymph node involvement Midline tumour which cannot be removed with a sufficiently wide margin due to infiltration of the surrounding tissues
<b>Stage 4</b>	Dissemination of the tumour to distant lymph nodes, skeleton, bone marrow, liver, skin and/or other organs
<b>Stage 4S</b>	Localised tumour as for Stages 1 and 2, with dissemination limited to the skin, liver and/or bone marrow (less than 10% infiltration) at age less than 1 year old

NBL is a highly aggressive tumour, with a few exceptions regarding cases which fall within stage 4S of the INSS classification, in which a progressive differentiation up to spontaneous remission may occur. Except for the rare INSS stage 4 cases, a neuroblastoma generally tends, as in the case presented here, to infiltrate the adjacent structures and organs, rapidly spreading to the nearby lymph nodes. As in this case, a single irregular mass with undefined borders is found at diagnosis, consisting of the primary mass and metastatic lymph nodes.

Neuroblastoma often produces catecholamines (this is why it is called a secreting tumour), causing high levels in the urine and blood, useful for diagnosis and monitoring.

In several cases, hypertension and tachycardia occur, although not always together with the increase in catecholamines and the other catabolites of the sympathetic system.

Neuroblastoma can affect the adrenal gland (presenting as an abdominal tumour) or the paraspinal sympathetic ganglia, and can also appear in any part of the vertebral column (abdominal and thoracic). Frequent signs of the disease include fever, anemia, loss of appetite, and bruising around the eyes. Metastases, which are frequent and appear early, affect the bones, the orbital region, the lymph nodes, the liver and bone marrow. Early diagnosis is fundamental as surgical intervention in the early stages increases survival; it is therefore necessary to test for the urinary metabolites of catecholamine (vanillylmandelic acid, homovanillic acid) and neuroendocrine markers (NSE). Ferritin and lactate dehydrogenase (LDH) are also parameters which should be evaluated when NBL is suspected.

The extent of the disease should be assessed with imaging procedures: CT, MRI, PET, and urography. In most cases, neuroblastoma presents with metastases when diagnosed. Cytogenetic analyses in neuroblastoma show a series of breakpoints of chromosome 1p from 1 P22 to 1 P 36. Chromosome 1 P allele deletions and loss are present not only in NBL, but in a wide range of solid and hematological tumours. The distal region of the short arm of chromosome 1 contains one or more genes implicated in the development of tumours.

## CLINICAL CASE

### Neuroblastoma (classification: T<sub>4</sub>N<sub>2</sub>M<sub>x</sub>): INSS stage 3

Patient details: Year of birth: 1998 – Sex: M

**CASE HISTORY** – Born in May 1998 with normal delivery, the child began to suffer continuous problems with his digestive system in November of the same year. As these problems gradually became worse, he was admitted to hospital in Avola, in Sicily, where ultrasound and CT scans, performed on 17/12/98, revealed a voluminous solid tumour in the left mid-lateral retroperitoneal area (4×8 cm) classified as a NBL. According to NBL

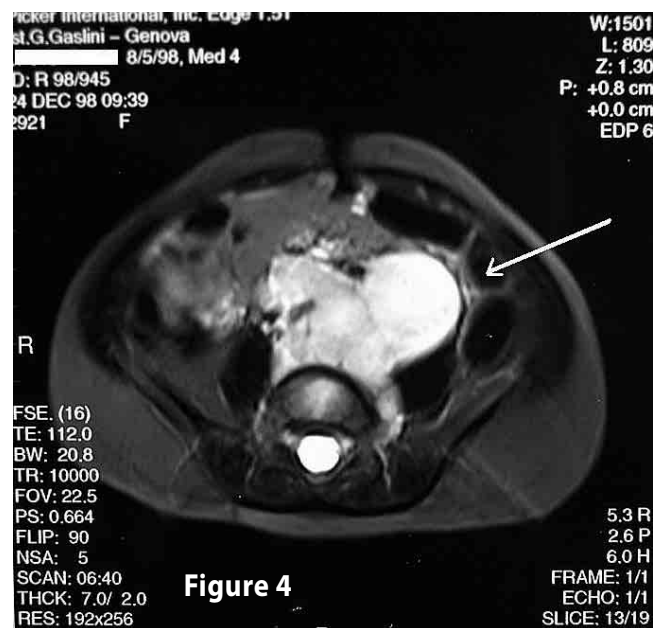
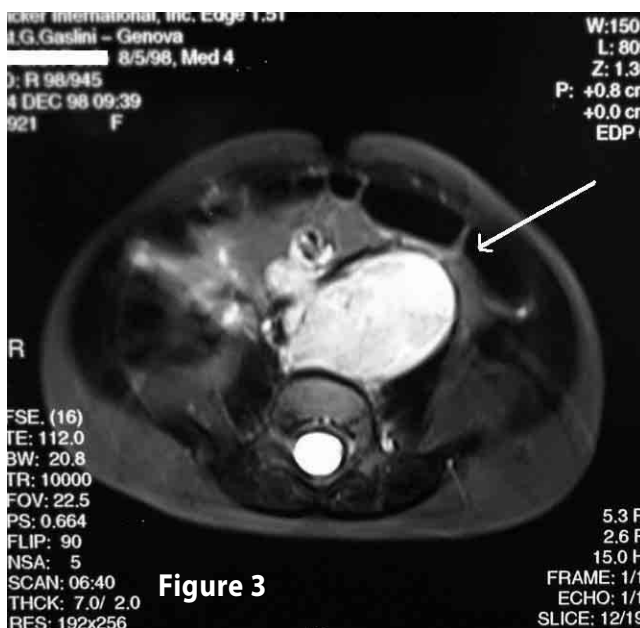
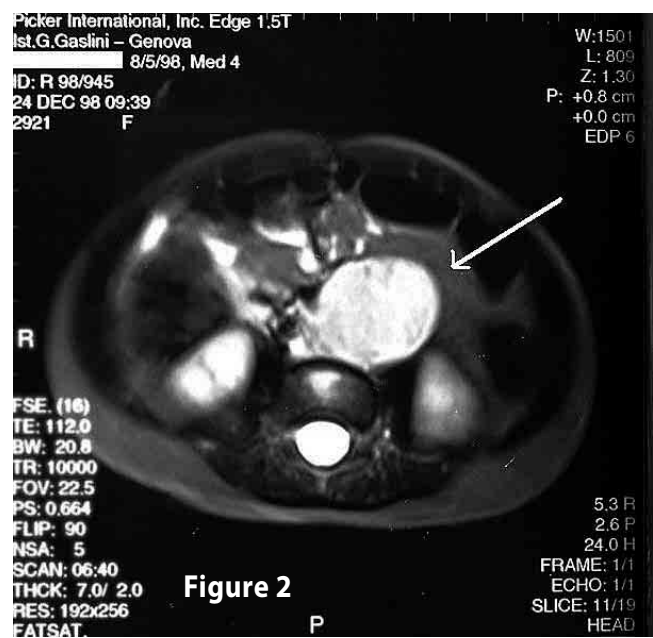
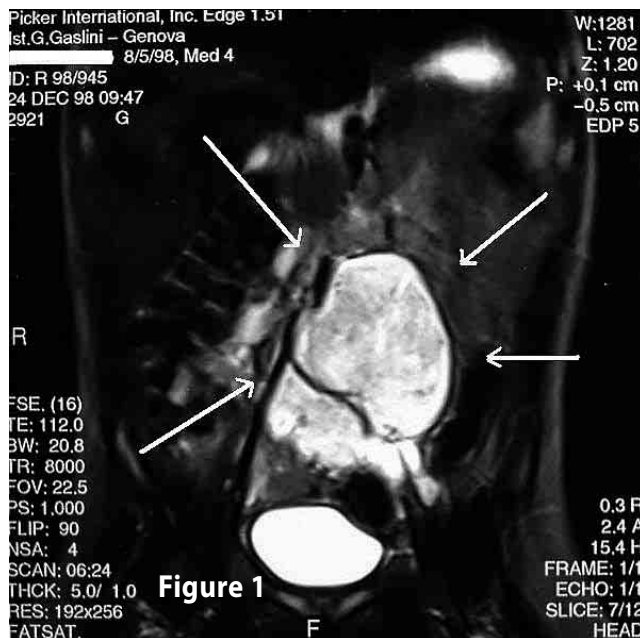
classification criteria (International Neuroblastoma Staging System) the case in question was clearly stage 3 (unoperable tumours infiltrating the midline with or without regional lymph node involvement).

### INITIAL ROUTINE TESTS

**Abdominal CT (17/12/98) – Report** – “CT of the upper and lower abdomen, performed in basal conditions, revealed the presence of a large solid formation in the left mid-lateral retroperitoneal area with a maximum width of around 4 cm. and a maximum length of around 8 cm.

*The structure of this formation is not uniform, and presents numerous calcifications; it has displaced the intestinal loops forward and the aorta towards the right, and is in close contact with the front margin of the spine. The CT appearance of this formation is compatible with neuroblastoma ...”*

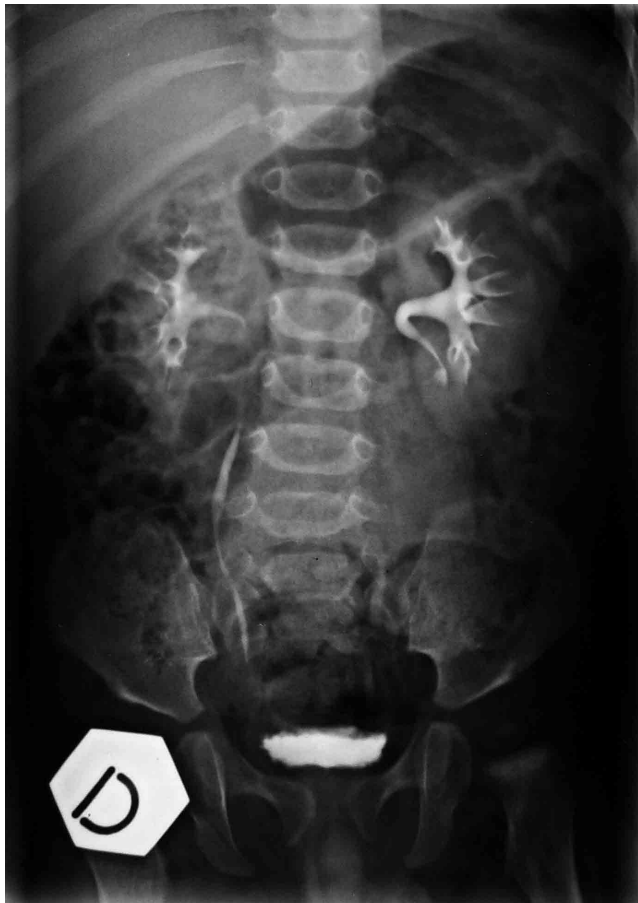After the CT scan, the child was transferred to the “Gaslini” Children’s Hospital in Genoa (Scientific Research and Care Institute), where MRI of the upper and lower abdomen and urography under general anesthesia were carried out on 24/12/98.



**Figures 1–4.** MRI (1998, Dec. 24 ): Confirmed presence of a large expansive process, extending caudally from the renal vascular pedicle to beyond the aorta-iliac division.

**MRI (24/12/1998) – Report:** “No secondary lesions evident in the liver. No lymphadenomegaly close to the aorta or vena cava. Normal kidneys and spleen. Confirmed presence of a large expansive process, extending caudally from the renal vascular pedicle to beyond the aorta-iliac division. The mass is midline, extending mainly towards the left (crossing the midline), with displacement of the homolateral psoas. The structure is solid without evidence of necrotic-colliquative phenomena. The signal is clearly hyper-intense in T2 with a hypo-intense diffuse punctiform appearance due to the presence of calcifications. The distal aorta and vena cava, the bifurcation and the iliac veins and arteries (more to the left) are marginally incorporated and displaced towards the right. No liquid in the peritoneum.”

**Urography (28/12/1998) – Report:** “Prompt elimination and regular concentration of the iodate contrast medium by both renal excretors. On the right, regular calyx-pyelic and ureteral morphology. On the left, normal calyx-pyelic morphology; the ureter presents a normal calibre but an altered course: in the anterior-posterior projection the proximal tract appears to be outwardly



**Figure 5.** Urography (1998, Dec.28): The ureter presents a normal calibre but an altered course: in the anterior-posterior projection the proximal tract appears to be outwardly displaced, while in the latero-lateral projection the intermediate tract appears to be pushed forward, probably displaced by the retroperitoneal mass.

displaced, while in the latero-lateral projection the intermediate tract appears to be pushed forward, probably displaced by the retroperitoneal mass.”

The diagnosis of neuroblastoma made at the hospital in Sicily was confirmed at the “Gaslini” Institute.

The parents were informed of the unacceptable risk of surgery, not only because of the child’s age but also due to the volume and the marked vascularisation of the tumoral mass, and above all for the difficulty in identifying cleavage planes with the distal aorta and the vena cava, the bifurcation and the iliac veins and arteries, all incorporated by the tumoral mass and displaced towards the left.

The particularly significant volume of the abdominal-pelvic tumour (8 cm × 4 in a 7-month-old baby) with displacement of the ureter and compression of the intestinal loops was causing gastrointestinal problems, colic and vomiting. Chemotherapy was proposed. An urgent solution was necessary due to the persistence of the gastrointestinal symptoms, the deterioration of the child’s condition and the rapid progression of the tumour. The parents refused chemotherapy and, in January 1999, the child was therefore discharged from the “Gaslini” hospital with a report to the Pediatric Clinic in Catania, specifying that: “the suspicion of Neuroblastoma was confirmed by the tests relative to the urinary excretion of sympathetic amines:

## PATHOLOGICAL HEMATO-CHEMICAL VALUES

*Vanillylmandelic acid: 35.6 gamma/mg – creatine*  
*Homovanillic acid: 79.7 gamma/mg – creatine*  
*NSE: 30 – LDH: 603*  
*Hemochrome: Hb 12.9 – WBC : 15900 (with normal leukocyte formula)*  
*Platelets: 474,000*  
*Abdominal MRI: large expansive process below the renal vascular pedicle, mainly on the left*  
*Intravenous urography: altered course of the left ureter*

## RESULTS

### Therapy and clinical course

The parents decided to refuse chemotherapy and to try the MDB.

The treatment prescribed by Prof. Luigi Di Bella and started immediately after the child was discharged from hospital is described below:

#### 1) *Solution of:*

- All-Trans-Retinoic Acid           0.5 g
  - Palmitate axerophthol           0.5 g
  - Beta carotene                       2 g
  - Alpha-tocopherol-acetate       1000 g
- one 2 ml teaspoonful of Solution every 3 hours together with:

- 2) **Dihydrotachysterol** (one drop in the teaspoon for each administration)
- 3) **Bromocriptine** 2.5 mg tablets (1/4 of a tablet twice a day, morning and evening)
- 4) **Melatonin 12%, Adenosine 51%, Glycine 37%** (one 5 mg vial diluted in water)
- 5) **Chondroitin sulfate** (one 500 mg vial orally with the evening feed/meal)
- 6) **Cyclophosphamide** 50 mg tablets (1/4 of a tablet with the main feed/meal)
- 7) **Somatostatin** – 14 amino acids (one 0.25 mg vial injected slowly subcutaneously in the evening).

The treatment was tolerated and blood tests were scheduled every 2 weeks.

The general conditions of the child improved, with a gradual reduction of the colic attacks, the diarrhea, vomiting and anorexia, and an increase in weight. By the end of 1999, the child's weight, height and psychophysical development were within the physiological range. The gradual remission of the symptoms was accompanied by a progressive return to normal of the hematochemical values, with a reduction of the leukocytes, ESR, LDH, Ferritin, catecholamines, NSE, vanillylmandelic acid and homovanillic acid. For the first few months, hemochrome was tested every 2 weeks. Complete hematochemical tests were carried out every 2–3 months since, in addition to a high diagnostic value, these are also useful for monitoring remission and to detect recurrences at an early stage, before any clinical signs become evident. The improvement of the hematochemical values was accompanied by a marked and continuous reduction in volume of the tumoral mass detected by imaging procedures. Forty days after starting the MDB, an abdominal ultrasound scan on 12/02/99 showed a reduction of the tumour, reporting: "...In the left ilio-pelvic area, close to the vertebral plane, a slightly irregular, egg-shaped neof ormation with fairly well-defined borders can be seen. It measures 70 mm (longitudinal) (on 17/12/08 80 mm) × 40 mm ...It has a solid and non-uniform structure due to the presence of countless isolated groups of microcalcification echo reflections. Color-doppler, hindered by the movements of the child, showed some intralesional vessels with a low resistance index. Nothing of note regarding the kidneys or the organs in the upper abdomen..."

The treatment was revised by Prof. Di Bella on 12/03/1999, altering the daily dose of Somatostatin from 0.25 mg/day to 0.5 mg on alternate days for 3 times a week, continuing with 0.25 mg on the other 4 days of the week, and leaving the rest of the treatment unchanged.

Six months after starting the therapy, an MRI on 18/06/1999 showed a regression of the tumour of around 50%.

**MRI (18/6/1999) – Report:** "...The procedure was carried out with the turbo-spin-echo technique, along the axial and coronal planes, with inversion-recovery

sequences and T2-weighted scans, after i.v. injection of gadolinium. Compared with the previous scan on 24/12/98, there is a notable reduction of the retroperitoneal tumour in the left para-aortic and paravertebral region, now measuring 5 cm in length and 2 cm in width. The liver, spleen, pancreas, kidneys and adrenal glands are not affected."

At the same time, the values of ESR, LDH, Ferritin, NSE, urinary excretion of Vanillylmandelic acid, Homovanillic acid and Catecholamines had returned to within the normal physiological range.

After one year of treatment, an MRI, carried out on 21/01/2000 in Catania, showed the almost total disappearance of the Neuroblastoma.

**MRI (21/1/2000) – Report:** "...The MRI was carried out with the spin-echo technique, along the axial and coronal planes, with inversion recovery sequences and T2-weighted scans, after i.v. injection of gadolinium. Compared with the previous scan on 18/06/99, the retroperitoneal neof ormation previously visible in the left para-aortic and paravertebral region has almost totally disappeared, now represented by a small residue in the para-aortic region. The other findings are as before."

In September 2000 (child's age: 28 months) Prof. Di Bella revised the treatment as follows:

1) **Solution of:**

- <b>All-Trans-Retinoic Acid</b>	0.5 g
- <b>Palmitate axerophthol</b>	0.5 g
- <b>Beta carotene</b>	2 g
- <b>Alpha-tocopherol-acetate</b>	1000 g

One 2.5 ml teaspoonful of Solution three times a day, morning – mid-day – evening (at least 15 minutes before meals) together with:

2) **Dihydrotachysterol** (4 drops in the teaspoon for each administration)

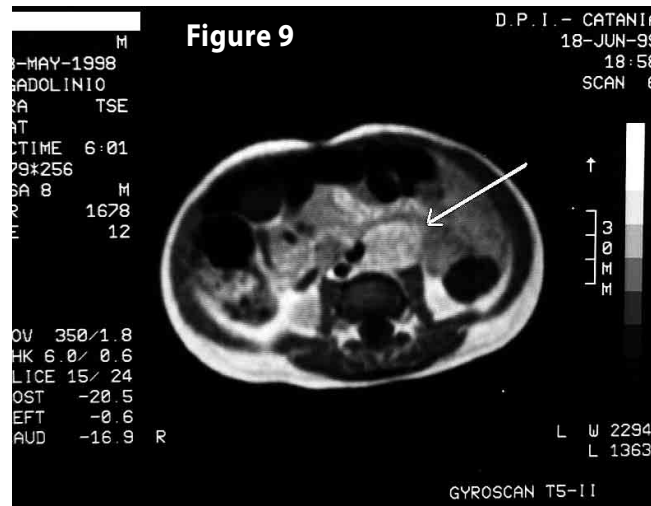
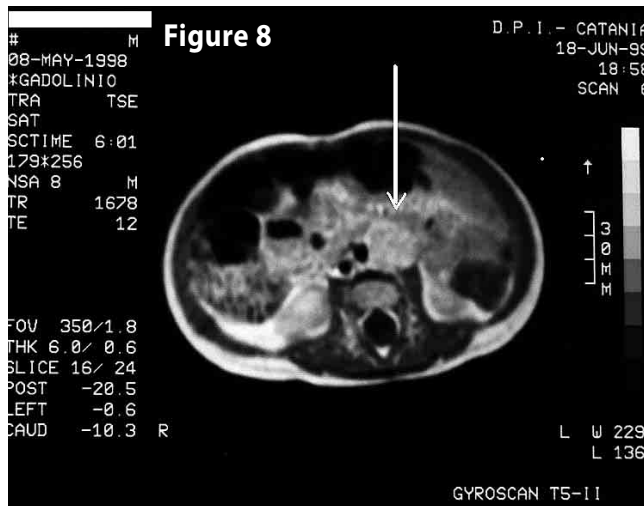
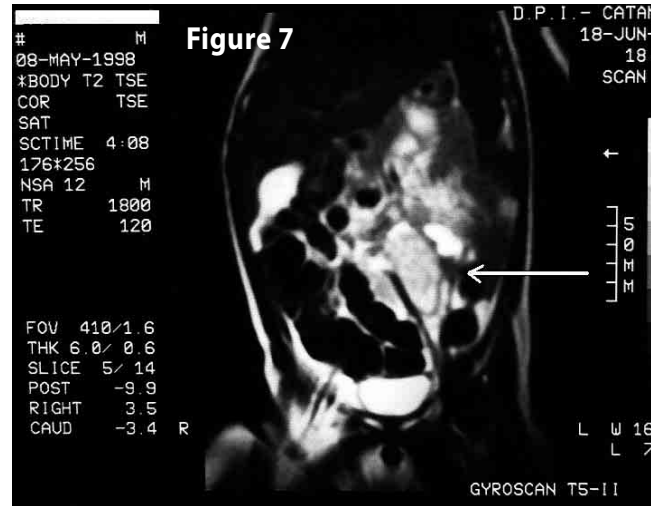
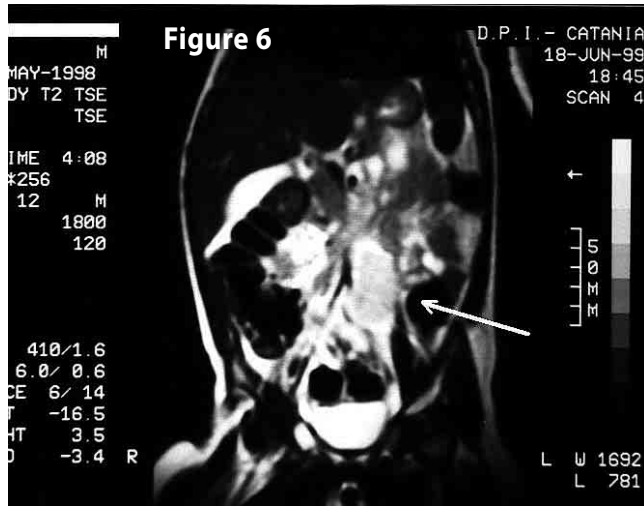
and the following products orally during the meal:

- 3) **Bromocriptine** 2.5 mg tablets (1/2 of a tablet, twice a day)
- 4) **Melatonin 12%, Adenosine 51%, Glycine 37%** (2 mg tablets – 2 tablets in the morning and at mid-day, 4 tablets before bed)
- 5) **Somatostatin** – 14 amino acids (one 0.75 mg vial injected slowly subcutaneously in the evening).

From 2001 the dose of Somatostatin was increased to 1 mg every evening, leaving the rest unchanged.

In March 2001 an MRI with contrast medium showed "the total absence of tumoral traces."

The treatment was further reduced by completely eliminating Cyclophosphamide, Bromocriptine, Chondroitin sulfate, and Calcium. The dose of Somatostatin was reduced to 1 mg subcutaneously on alternate days 3 times a week. From 2002 the administration of



**Figures 6–9.** MRI (1999, Jun. 18): Compared with the previous scan on 24/12/98, there is a notable reduction of the retroperitoneal tumour in the left para-aortic and paravertebral region, now measuring 5 cm in length and 2 cm in width.

Somatostatin was limited to 1 mg a week, from 2003 1 mg every 15 days, and then completely discontinued in 2007, while at the time of writing the administration continues of retinoids with 8 drops of Vit.D<sub>3</sub> (Dihydro-achysterol) every morning before eating, and four 2 mg tablets of MLT after the evening meal.

Since 2001 all the subsequent blood tests and imaging procedures (PET, MRI) have confirmed the absence of disease with complete remission of the NBL.

**PET (07/10/2003) – Report:** “Absence of areas of pathological accumulation of the metabolic trace agent ... The PET scan does not show any alterations that can be attributed to the presence of surrogate disease with high metabolic activity.”

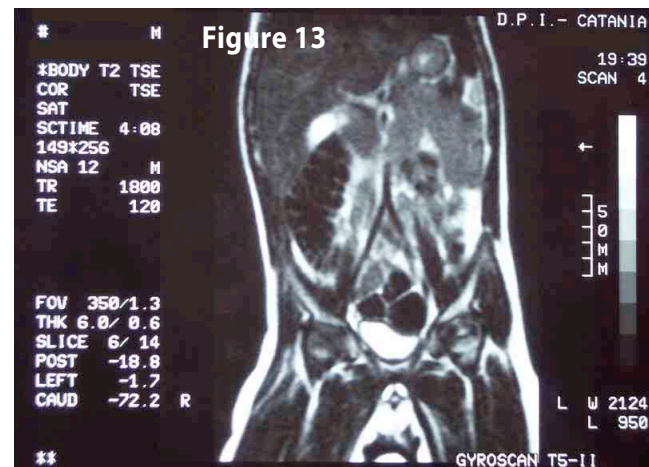
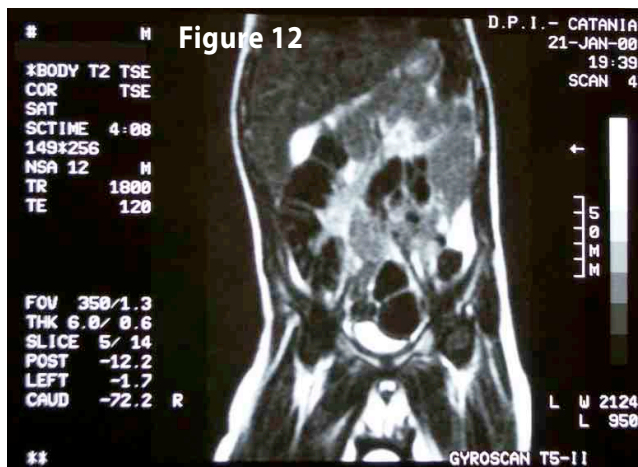
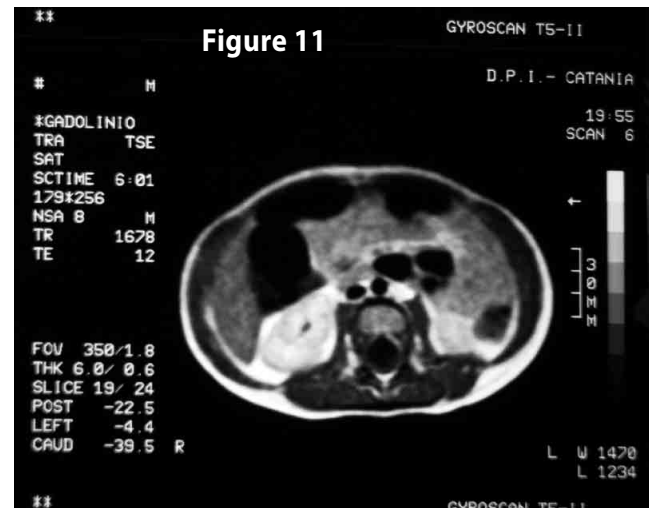
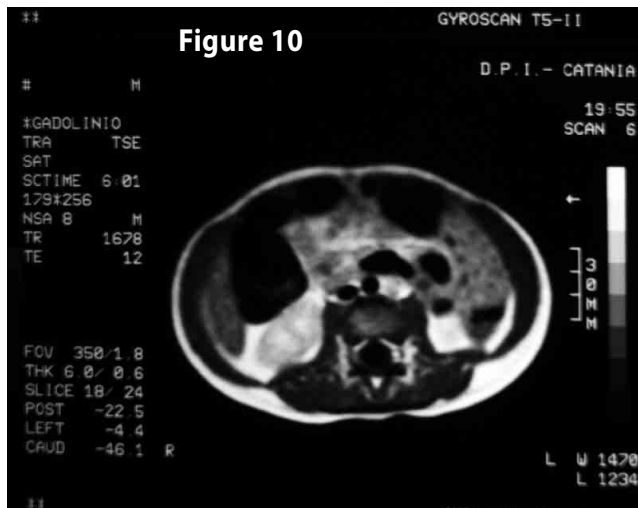
**PET (20/09/2004) – Report:** “No evidence of pathological accumulation of the metabolic trace agent ... The PET scan does not show any alterations that can be attributed to the presence of surrogate disease with high metabolic activity” (Figure 7)

**MRI (06/10/2005) – Report:** “... Complete macroscopic regression of the expansive tumoral lesion localised in the abdominal-pelvic retroperitoneal area and incorporating the left iliac vessels ...”(Figure 8)

**PET (17/3/2008) – Report:** “Today’s follow-up PET scan, compared with the previous scans in 2003 and 2004, does not show any evidence of pathological accumulation of the metabolic trace agent in the explored area. In particular, nothing to report in the abdomen...”

## DISCUSSION

The biological neuro-immuno-endocrine therapy prescribed by Prof. Luigi Di Bella (MDB) achieved a complete objective response in fourteen months, with no toxicity. by means of a receptorial, differentiating, apoptotic and antiproliferative mechanism of action, with criteria, methods and mechanisms of action totally different to the usual cytotoxic and cytolytic treatments, proving that it can replace surgery, and radiotherapy



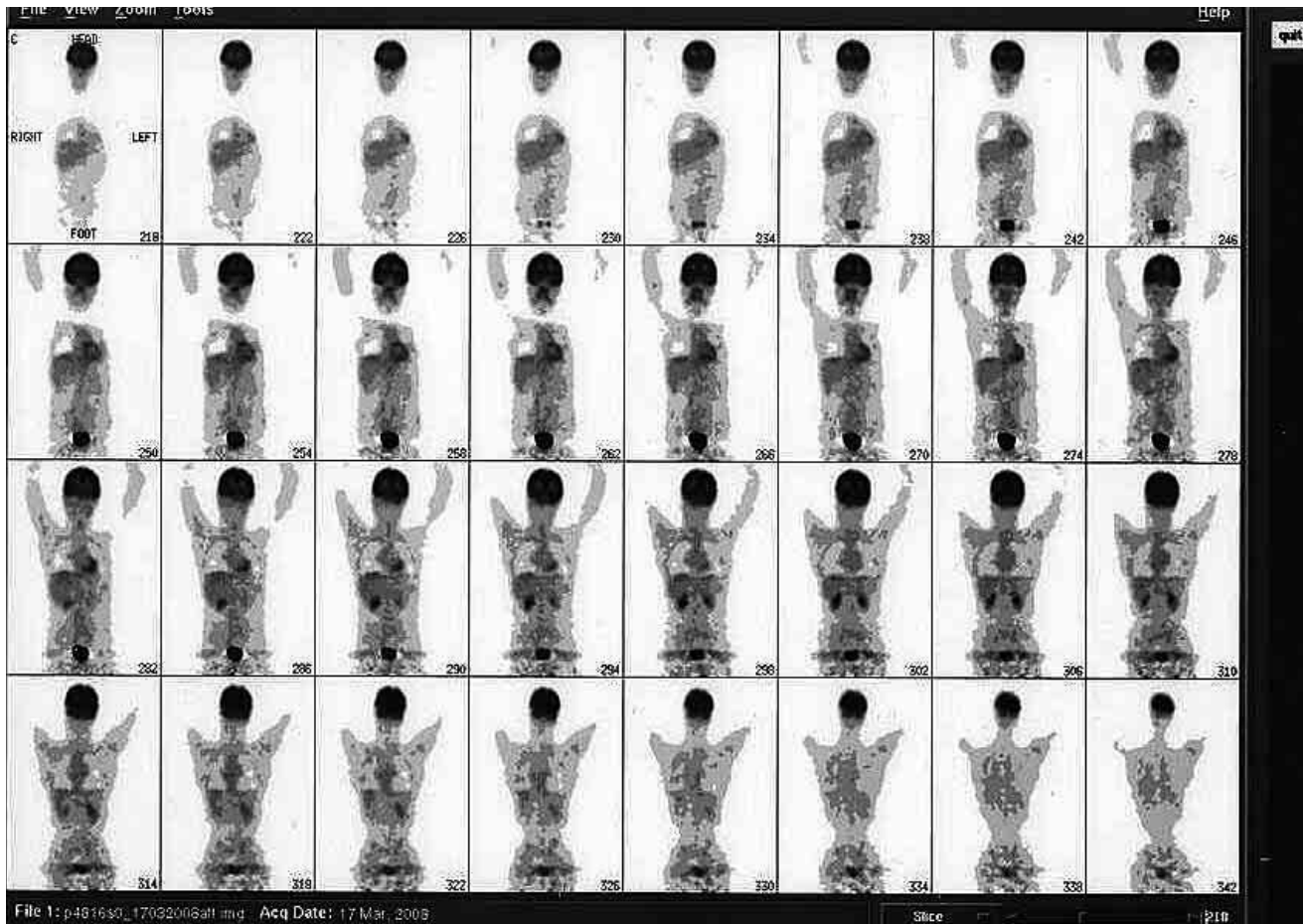
Figures 10–13. MRI (2000, Gen. 21): The retroperitoneal neof ormation previously visible in the left para-aortic and paravertebral region has almost totally disappeared, now represented by a small residue in the para-aortic region.

and/or chemotherapy which are in any case unable to provide results that are comparable to surgery but which may precede or follow it.

### Rationale of the Therapy

The ubiquitous receptorial expression of Prolactin and GH (De Souza *et al.*, 1974; Hooghe *et al.*, 1998; Tada *et al.* 1999; Ben-Jonathan *et al.*, 2002) represents one of the aspects of the direct and generalised mitogenic role of these molecules. The use of SST and/or Octreotide in all tumoral diseases is widely justified by the negative regulation of GH, a hormone with a high mitogenic potential, GH-correlated mitogenic growth factors and neoplastic angiogenesis. This justifies the use of somatostatin and its analogs in all tumors (Di Bella *et al.*, 1979; Manni *et al.*, 1989; Klijn *et al.*, 1996; Pollak *et al.*, 1997; Pawlikowski *et al.*, 1998; Lachowicz-Ochedalska *et al.*, 2000; Friend *et al.*, 2000; Schally *et al.* 2001; Schally *et al.*, 2003; Massa *al.*, 2004; Arena *et al.*, 2007; Guillermet-Guibert *et al.*, 2007; Lee *et al.*, 2008) with

particular efficacy in neuroendocrine tumours such as NBL, characterised by a high receptorial expression for somatostatin (Moertel *et al.*, 1994; Sestini *et al.*, 1996; Kogner *et al.*, 1997; Briganti *et al.*, 1997; Borgström, 1999; Friend *et al.*, 2000; Steták *et al.*, 2001; Orlando *et al.* 2001; Florio *et al.*, 2008). SSTRs have also been identified in a wide range of non-neuroendocrine tumours (Schaer *et al.*, 1997; Van Eijck *et al.*, 1998; Held-Feindt *et al.*, 1999; Mishima *et al.*, 1999; Pinzani *et al.*, 2001; Watson *et al.*, 2001; Barnett *et al.*, 2003). A causal relationship has been demonstrated between GH (of which SST is the biological antidote) and tumoral induction and progression (Zeitler *et al.*, 2000), by histochemically detecting markedly higher concentrations of GHR in tumoral tissue with respect to healthy tissue. The powerful mitogenic role of GH, with a proliferative index and speed of progression of the neoplastic population directly proportional to the receptorial expression of GH, is therefore known and documented (Lincoln *et al.*, 1998). The loss of differentiation and the



**Figure 14.** PET (2008, Mar. 17): Does not show any evidence of pathological accumulation of the metabolic trace agent in the explored area. In particular, nothing to report in the abdomen.

uncontrolled proliferation, albeit to different extents, are common denominators of all tumours. Through a differentiating and antiproliferative factorial synergic mechanism, the other components of the MDB reinforce the antitumoral activity of SST.

#### **Interaction of the MDB with the cytogenetic and molecular aspects of NBL**

In NBL the loss of heterozygotes 1 P (1P LOH) is associated with amplification of the oncogene N- MIC, which is not ascertained in only 3% of cases. The inhibition of various oncogenes, including MIC by some of the components of the MDB, has been documented (Degli Uberti *et al.*, 1991; Peverali *et al.*, 1996; Sun *et al.*, 2002; Gumireddy *et al.*, 2003; Durand *et al.*, 2008; Aktas *et al.*, 2009). The chromosome damage of NBL leads to varying degrees of inactivation of oncosuppressor genes: CD 44, Bcl-2, P53, as well as Caspase 3–8, key elements of the apoptotic cascade. Oncosuppressor inactivation occurs simultaneously with the amplification of oncogenes such as the N-myc gene and the proto oncogene TRK, considered one of the cytogenetic causes of neuroblastoma. The negative regulation of the oncosuppressors is also antagonised by the components of the

MDB, such as retinoic acid which inhibits the inactivation of caspase (Piedrafita 1997; Takada *et al.* 2001; Jiang *et al.* 2008) and MLT which protects P53 and Bcl-2 from degradation (Mediavilla *et al.* 1999). One of the pathogenetic factors of NBL is the altered response of the neuroblasts to the differentiating stimulation, effectively countered by the retinoids which induce neuronal differentiation (Hassan *et al.* 1990; Giannini *et al.* 1997; Peverali *et al.* 1998; Voigt *et al.* 2000, Ueda *et al.*, 2001; Kulikov *et al.* 2007; Beijersbergen *et al.* 2009; Wu *et al.* 2009; Witzigmann *et al.* 2008). The differentiation is synergically reinforced by other components of the MDB, such as MLT (Cos *et al.* 1996; Garcia-Santos *et al.* 2006; McMillan *et al.* 2007), Vit D3 (Lange *et al.* 2007), Vit E (Turley *et al.* 1995; Swettenham *et al.* 2005), Vit C (Carosio *et al.*, 2007) and Chondroitin sulfate (Batra *et al.*, 1997; Pumphrey *et al.*, 2002).

In NBL there is an alteration of the NGF-TRK receptor-ligand system, consisting of the interaction between families of transmembrane receptors and tyrosine-kinase A-B-C activity, and ligands consisting of trophism and central and peripheral nervous growth systems, represented by nerve growth factor (NGF), neurotrophines (NT3-4-5), and Brain Derived Neurotrophic Factor



(BDNF). Components of the MDB such as STT and retinoids (Giannini *et al.*, 1997; Witzigmann *et al.* 2008; Liang *et al.* 2009) antagonise the proliferative stimulus of these molecules. The binding of NGF, NT and BDNF to TRK receptors induces the transactivation and phosphorylation of tyrosine residues with the start of a cascade of intracellular events aimed at cellular proliferation. The neuroblastoma cells contain various levels of expression of tyrosine kinase receptors. The Protein-Tyrosine kinase activity is effectively inhibited by SST and its analogs (Reardon 1996 *et al.*; Pawlikowski *et al.* 1998; Lachowicz-Ochedalska *et al.* 2000; Cattaneo *et al.* 2000; Florio *et al.* 2001; Massa *et al.* 2004; Lee *et al.* 2008; Florio *et al.* 2007). The molecular equivalent of the clinical-prognostic aspects is regulated in the most aggressive NBLs by the reduced or non-expression of TRK -A, the increased expression of TRK-B and amplification of N- Myc negatively regulated by SST (Degli Uberti *et al.* 1991; Sun 2002 *et al.*; Durand *et al.* 2008 ). In NBLs with the worst prognosis there is little or no expression of CD44 and TRK-A, present due to MRP, together with high telomeric activity. On the contrary, the decrease of TRK-B and N- Myc, together with the increased expression of TRK-A, is connected with a favourable prognosis, as is a high expression of somatostatin receptors (always present in NBLs).

#### Antiblastic molecular mechanisms of action of MDB

Cellular proliferation is strictly dependent on prolactin, GH, the main growth factor, and on GH-dependent mitogenic molecules, positively regulated by GH, such as EGF, FGF, HGF, IGF1-2, NGF, PDGF, VEGF and TGF, as well as by growth factors produced by the digestive tract, such as Gastrin, VIP, and CCK, also negatively regulated by SST (Kath *et al.*, 2000). Both physiological and neoplastic cellular proliferation are triggered by these molecules, which are used to a much greater extent by the tumour cells than by healthy cells. Biological antidotes of GH, Somatostatin and its analogs, do not merely reduce the expression and transcription of highly mitogenic growth factors, such as IGF1-2 (Sall *et al.*, 2004), EGF (Szepesházi *et al.*, 1999) and FGF (Held-Feindt *et al.*, 1999), but extend their negative regulation to the respective receptors with evident antiproliferative (Mishima *et al.* 1999) and antiangiogenic effects (Barrie *et al.*, 1993; Albini *et al.* 1999; Vidal *et al.* 2000; Watson *et al.*, 2001; Bocci *et al.* 2007).

It is known that the GH-IGF1 axis has a determining influence on neoplastic biological development (Murray *et al.* 2004). The IGF1R respond mitogenically to IGF. The suppressive effect of SST and its analogs on serum levels of IGF1 is both direct, through inhibition of the IGF gene, and indirect, through the suppression of GH and thus of its hepatic induction of IGF1 (Sall *et al.* 2004).

It has been widely documented that neoplastic progression is strictly dependent on angiogenesis which

represents an obligatory and essential phase. Somatostatin and its analogs negatively regulate all stages of angiogenesis, such as the cascade of monocytes (Wiedermann *et al.*, 1993), interleukin 8, Prostaglandin E 2, and endothelial Nitric oxide synthase (e-Nos) (Florio *et al.*, 2003), as well as growth factors whose synergy is essential for angiogenesis, such as VEGF (Cascinu *et al.*, 2001; Mentlein *et al.*, 2001) TGF, IGF1 (Murray *et al.*, 2004; Hagemester *et al.*, 2008) FGF, HGF (Jia *et al.*, 2003; Hagemester *et al.* 2008), PDGF (Cattaneo *et al.*, 1999), and EGF (Mishima *et al.*, 1999; Szepesházi *et al.*, 1999; Held-Feindt *et al.*, 1999). The inhibition of angiogenesis induced by SST is synergically and factorially reinforced by the other components of the MDB such as MLT (Di Bella *et al.*, 2006; Lissoni *et al.* 2001), retinoids (Majewski *et al.*, 1994; McMillan K. *et al.*, 1999; Kini *et al.*, 2001), vitamin D3 (Kisker *et al.*, 2003; Mantell *et al.*, 2000), Vitamin E (Shklar *et al.*, 1996; Tang *et al.*, 2001), Vitamin C (Ashino *et al.*, 2003), prolactin inhibitors (Turner *et al.*, 2000), and components of the extracellular matrix (Ozerdem *et al.*, 2004; Liu *et al.*, 2005).

In a similar way, the cytostatic, antiproliferative and antimetastatic effect of Somatostatin (Kogner *et al.* 1997; Orlando *et al.* 2001; Arena *et al.* 2006; Guillermet-Guibert *et al.* 2007; Barbieri *et al.* 2008) is effectively synergised by the other components of the MDB, such as retinoids (Hassan *et al.* 1990; Onogi *et al.*, 1998; Piedrafita *et al.*, 1997; Voigt *et al.*, 2000; Witzigmann *et al.*, 2008), MLT (Kvetnoi *et al.*, 1986; Maestroni *et al.*, 1996; Cos *et al.* 2000; Bartsch *et al.*, 1999; Mediavilla *et al.*, 1999; Garcia-Santos, *et al.* 2006; Pizarro *et al.*, 2008), Vit D3 (Celli *et al.*, 1999; Barroga *et al.* 2000; Campbell *et al.* 2000; Jensen *et al.* 2001; Stio *et al.*, 2001), the prolactin inhibitors Cabergoline and Bromocriptine (Manni *et al.*, 1989; Klijn *et al.*, 1996; Gruszka *et al.*, 2001), Galactosamine sulfate, components of the extracellular matrix (Batra *et al.*, 1997; Pumphrey *et al.*, 2002), Vit E (Turley *et al.*, 1995; Shklar *et al.*, 1996; Israel *et al.*, 2000; Malafa *et al.* 2002; Neuzil *et al.* 2002) and Vit C (Cameron *et al.*, 1979; Murata *et al.* 1982; Head *et al.* 1998; Carosio *et al.* 2007). The literature has therefore confirmed the synergic antineoplastic, differentiating, antiproliferative, antiangiogenic and antimetastatic mechanisms of action of all the components of the MDB

The objective result, with no toxicity, of the rapid reduction and disappearance of a retroperitoneal mass measuring 4x8 cm in a seven-month-old child, together with the blocking of all metastatic dissemination, demonstrates the efficacy of this treatment and is in agreement with the positive results achieved with the use of the MDB in lymphoproliferative diseases (Todisco *et al.* 2001; Todisco *et al.*, 2006; Todisco *et al.* 2009), stage 3 and 4 lung cancer (Norsa *et al.* 2006 ; Norsa *et al.* 2007), breast cancer (Di Bella *et al.*, 2009). Without the need for hospitalisation or even day hospital, and without in any way impairing the psychophysical development of the child, the MDB avoided difficult radical surgery,

which also involved a high risk since the distal aorta and vena cava, the bifurcation and the iliac arteries and veins were incorporated and displaced by the tumoral mass. It also made it possible to avoid chemo- and radiotherapy with their known and serious contraindications.

The blood tests and the diagnostic procedures showed a progressive decrease in the volume of the tumour, together with a reduction of the amine metabolites of the adrenergic system that are typical of neuroblastoma, such as catecholamine, Vanillylmandelic acid and Homovanillic acid, together with neuroendocrine markers such as NSE, and molecules like Ferritin and HDL which are typical of this disease. The complete objective result in little more than a year, together with the blocking of all metastatic dissemination, frequent in NBL, shows the efficacy of this treatment. The continuous administration of the components of the MDB for over 10 years was perfectly tolerated, allowing immunitary and neuroendocrine homeostasis well within physiological limits, and excellent psychophysical development.

The early application of the MDB as a first line therapy in a patient who was not weakened by the toxic, mutagenic and immunodepressive effects of chemoradiotherapy was of considerable help to the result. We believe it is of use to report this case to invite greater interest and more detailed research into the possibilities offered in the oncological field by the immunoneuroendocrine, biological and receptorial treatment of the MDB.

## REFERENCES

- Aktas S, Altun Z, Erbayraktar N (2009). Effect of Cytotoxic Agents and Retinoic Acid on Myc-N Protein Expression in Neuroblastoma. *Appl Immunohistochem Mol Morphol*. Jun 22. (Epub ahead of print).
- Albini A, Florio T, Giunciuglio D, Masiello L, Carlone S, Corsaro A, *et al.* (1999). Somatostatin controls Kaposi's sarcoma tumor growth through inhibition of angiogenesis. *FASEB J*. **13**(6): 647-655.
- Arena S, Pattarozzi A, Massa A (2007). An intracellular multi-effector complex mediates somatostatin receptor 1 activation of phospho-tyrosine phosphatase eta. *Mol Endocrinol*. Jan **21**(1): 229-46.
- Ashino H, Shimamura M, Nakajima H, Dombou M, Kawanaka S, Oikawa T, *et al.* (2003). Novel function of ascorbic acid as an angiostatic factor. *Angiogenesis*. **6**(4): 259-269.
- Barbieri F, Pattarozzi A, Gatti M (2008). Somatostatin receptors 1, 2, and 5 cooperate in the somatostatin inhibition of C6 glioma cell proliferation in vitro via a phosphotyrosine phosphatase-eta-dependent inhibition of extracellularly regulated kinase-1/2. *Endocrinology*. **149**(9): 4736-46.
- Barnett P (2003). Somatostatin and somatostatin receptor physiology. *Endocrine*. **20**(3): 255-264.
- Barrie R, Woltering EA, Hajarizadeh H, Mueller C, Ure T, Fletcher WS (1993). Inhibition of angiogenesis by somatostatin and somatostatin-like compounds is structurally dependent. *J Surg Res*. **55**(4): 446-450.
- Barroga EF, Kadosawa T, Okumura M, Fujinaga T (2000). Inhibitory effects of 22-oxa-calcitriol and all- trans retinoic acid on the growth of a canine osteosarcoma derived cell-line in vivo and its pulmonary metastasis in vivo. *Res Vet Sci*. **68**(1): 79-87.
- Bartsch C, Bartsch H, Buchberger A, Stieglitz Effenberger-Klein A, Kruse-Jarres JD, *et al.* (1999). Serial transplants of DMBA-induced mammary tumors in Fischer rats as a model system for human breast cancer VI. The role of different forms of tumor-associated stress for the regulation of pineal melatonin secretion. *Oncology*. **56**(2): 169-176
- Batra RK, Olsen JC, Hoganson DK, Caterson B, Boucher RC (1997). Retroviral gene transfer is inhibited by chondroitin sulfate proteoglycans/glycosaminoglycans in malignant pleural effusions. *J Biol Chem*. **272**(18): 11736-43.
- Beijersbergen RL, Bernards R (2009). ZNF423 is critically required for retinoic acid-induced differentiation and is a marker of neuroblastoma outcome. *Cancer Cell*. **15**(4): 328-40.
- Ben-Jonathan N, Liby K, McFarland M, Zinger M (2002). Prolactin as an autocrine/paracrine growth factor in human cancer. *Trends Endocrinol Metab*. **13**(6): 245-250.
- Bocci G, Culler MD, Fioravanti A (2007). In vitro antiangiogenic activity of selective somatostatin subtype-1 receptor agonists. *Eur J Clin Invest*. **37**(9): 700-8.
- Borgström P, Hassan M (1999). The somatostatin analogue octreotide inhibits neuroblastoma growth in vivo. *Pediatr Res*. **46**(3): 328-32.
- Briganti V, Sestini R, Orlando C (1997). Imaging of somatostatin receptors by indium-111-pentetreotide correlates with quantitative determination of somatostatin receptor type 2 gene expression in neuroblastoma tumors. *Clin Cancer Res*. **3**(12 Pt 1): 2385-91.
- Cameron E, Pauling L, Leibovitz B (1979). Ascorbic acid and cancer: a review. *Cancer Res*. **39**(3): 663-681.
- Campbell MJ, Gombart AF, Kwok SH, Park S, Koeffler HP (2000). The anti-proliferative effects of 1alpha,25(OH)2D3 on breast and prostate cancer cells are associated with induction of BRCA1 gene expression. *Oncogene*. **19**(44): 5091-7.
- Carosio R, Zuccari G, Orienti I (2007). Sodium ascorbate induces apoptosis in neuroblastoma cell lines by interfering with iron uptake. *Mol Cancer*. **6**: 55.
- Cascinu S, Del Ferro E, Ligi M, Staccioli MP, Giordani P, Catalano V, *et al.* (2001). Inhibition of vascular endothelial growth factor by octreotide in colorectal cancer patients. *Cancer Invest*. **19**(1): 8-12.
- Cattaneo mg, Taylor JE, Culler MD (2000). Selective stimulation of somatostatin receptor subtypes: differential effects on Ras/MAP kinase pathway and cell proliferation in human neuroblastoma cells. *FEBS Lett*. **481**(3): 271-6.
- Cattaneo mg, Scita G, Vicentini LM (1999). Somatostatin inhibits PDGF-stimulated Ras activation in human neuroblastoma cells. *FEBS Lett*. **459**(1): 64-8.
- Celli A, Treves C, Nassi P (1999). Role of 1,25-dihydroxyvitamin D3 and extracellular calcium in the regulation of proliferation in cultured SH-SY5Y human neuroblastoma cells. *Neurochem Res*. **24**(5): 691-8.
- Cos S, Sánchez-Barceló EJ (2000). Melatonin and mammary pathological growth. *Front Neuroendocrinol*. **21**(2): 133-170.
- Cos S, Verduga R, Fernández-Viadero C (1996). Effects of melatonin on the proliferation and differentiation of human neuroblastoma cells in culture. *Neurosci Lett*. **216**(2): 113-6.
- De Souza I, Morgan L, Lewis UL, Raggatt PR, Salih H, Hobbs JR (1974). Growth-hormone dependence among human breast cancers. *Lancet*. **2**(7874): 182-184.
- Degli Uberti EC, Hanau S, Rossi R (1991). Somatostatin reduces 3H-thymidine incorporation and c-myc, but not thyroglobulin ribonucleic acid levels in human thyroid follicular cells in vitro. *J Clin Endocrinol Metab*. **72**(6): 1364-71.
- Di Bella L, Rossi MT, Scalera G (1979). Perspectives in pineal functions. *Prog Brain Res*. **52**: 475-478.
- Di Bella L, Gualano L (2006). Key aspects of melatonin physiology: thirty years of research. *Neuro Endocrinol Lett*. **27**(4): 425-432.
- Di Bella G (2009). Complete objective response to biological therapy of plurifocal breast carcinoma. *Neuro Endocrinol Lett*. **29**(6): 857-66.

- 30 Durand A, Champier J, Jouvet A, Labrousse F, Honnorat J, Guyotat J, Fèvre-Montange M (2008). Expression of c-Myc, neurofibromatosis Type 2, somatostatin receptor 2 and erb-B2 in human meningiomas: relation to grades or histotypes. *Clin Neuropathol.* **27**(5): 334–45.
- 31 Florio T, Morini M, Villa V, Arena S, Corsaro A, Thellung S, *et al.* (2003). Somatostatin inhibits tumor angiogenesis and growth via somatostatin receptor-3-mediated regulation of endothelial nitric oxide synthase and mitogen-activated protein kinase activities. *Endocrinology.* **144**(4): 1574–1584.
- 32 Florio T (2008). Molecular mechanisms of the antiproliferative activity of somatostatin receptors (SSTRs) in neuroendocrine tumors. *Front Biosci.* **13**: 822–40. Review.
- 33 Florio T (2008). Somatostatin/somatostatin receptor signaling: phosphotyrosine phosphatases. *Mol Cell Endocrinol.* **14** **286**(1–2): 40–8.
- 34 Florio T, Arena S, Thellung S, *et al.* (2001). The activation of the phosphotyrosine phosphatase eta (r-PTP eta) is responsible for the somatostatin inhibition of PC C13 thyroid cell proliferation. *Mol Endocrinol.* **15**(10): 1838–52.
- 35 Friend KE (2000). Targeting the growth hormone axis as a therapeutic strategy in oncology. *Growth Horm IGF Res. Suppl A*: S45–6. Review.
- 36 García-Santos G, Antolín I, Herrera F (2006). Melatonin induces apoptosis in human neuroblastoma cancer cells. *J Pineal Res.* **41**(2): 130–5.
- 37 Giannini G, Dawson MI, Zhang X (1997). Activation of three distinct RXR/RAR heterodimers induces growth arrest and differentiation of neuroblastoma cells. *J Biol Chem.* **272**(42): 26693–701.
- 38 Gruszka A, Pawlikowski M, Kunert-Radek J (2001). Anti-tumoral action of octreotide and bromocriptine on the experimental rat prolactinoma: anti-proliferative and pro-apoptotic effects. *Neuro Endocrinol Lett.* **22**(5): 343–348.
- 39 Guillermet-Guibert J, Saint-Laurent N, Davenne L (2007). Novel synergistic mechanism for sst2 somatostatin and TNF $\alpha$  receptors to induce apoptosis: crosstalk between NF-kappaB and JNK pathways. *Cell Death Differ.* **14**(2): 197–208.
- 40 Gumireddy K, Reddy GS, Ikegaki N (2003). Anti-proliferative effects of 20-epi-vitamin-D3 analogue, KH1060 in human neuroblastoma: induction of RAR-beta and p21(Cip1). *Cancer Lett.* **190**(1): 51–60.
- 41 Hagemester AL, Sheridan MA (2008). Somatostatin inhibits hepatic growth hormone receptor and insulin-like growth factor I mRNA expression by activating the ERK and PI3K signaling pathways. *Am J Physiol Regul Integr Comp Physiol.* **295**(2): R490.
- 42 Hassan HT, Rees J (1990). Triple combination of retinoic acid plus actinomycin D plus dimethylformamide induces differentiation of human acute myeloid leukaemic blasts in primary culture. *Cancer Chemother Pharmacol.* **26**(1): 26–30.
- 43 Head KA (1998). Ascorbic acid in the prevention and treatment of cancer. *Altern Med Rev.* **3**(3): 174–186.
- 44 Held-Feindt J, Krisch B, Mentlein R (1999). Molecular analysis of the somatostatin receptor subtype 2 in human glioma cells. *Brain Res Mol Brain Res.* **64**(1): 101–7.
- 45 Hooghe R, Merchav S, Gaidano G, Naessens F, Matera L (1998). A role for growth hormone and prolactin in leukaemia and lymphoma? *Cell Mol Life Sci.* **54**(10): 1095–1101.
- 46 Israel K, Yu W, Sanders BG, Kline K (2000). Vitamin E succinate induces apoptosis in human prostate cancer cells: role for Fas in vitamin E succinate-triggered apoptosis. *Nutr Cancer.* **36**(1): 90–100.
- 47 Jensen SS, Madsen MW, Lukas J, Binderup L, Bartek J (2001). Inhibitory effects of 1 $\alpha$ ,25-dihydroxyvitamin D(3) on the G(1)-S phase-controlling machinery. *Mol Endocrinol.* **15**(8): 1370–1380.
- 48 Jia WD, Xu GL, Xu RN, Sun HC, Wang L, Yu JH, *et al.* (2003). Octreotide acts as an antitumor angiogenesis compound and suppresses tumor growth in nude mice bearing human hepatocellular carcinoma xenografts. *J Cancer Res Clin Oncol.* **129**(6): 327–334.
- 49 Jiang M, Zhu K, Grenet J, Lahti JM (2008). Retinoic acid induces caspase-8 transcription via phospho-CREB and increases apoptotic responses to death stimuli in neuroblastoma cells. *Biochim Biophys Acta.* **1783**(6): 1055–67.
- 50 Kath R, Höffken K (2000). The significance of somatostatin analogues in the antiproliferative treatment of carcinomas. *Recent Results Cancer Res.* **153**: 23–43.
- 51 Kini AR, Peterson LA, Tallman MS, Lingen MW (2001). Angiogenesis in acute promyelocytic leukemia: induction by vascular endothelial growth factor and inhibition by all-trans retinoic acid. *Blood.* **97**(12): 3919–3924.
- 52 Kisker O, Onizuka S, Becker CM, Fannon M, Flynn E, D'Amato R, *et al.* (2003). Vitamin D binding protein-macrophage activating factor (DBP-maf) inhibits angiogenesis and tumor growth in mice. *Neoplasia.* **5**(1): 32–40.
- 53 Klijn JG, Setyono-Han B, Bontenbal M, Seynaeve C, Foekens J (1996). Novel endocrine therapies in breast cancer. *Acta Oncol.* **35** Suppl 5: 30–37.
- 54 Kogner P, Borgström P, Bjellerup P (1997). Somatostatin in neuroblastoma and ganglioneuroma. *Eur J Cancer. Oct* **33**(12): 2084–9.
- 55 Kulikov AV, Rzhainova AA, Goldshtein DV (2007). Expression of NMDA receptors in multipotent stromal cells of human adipose tissue under conditions of retinoic acid-induced differentiation. *Bull Exp Biol Med.* **144**(4): 626–629.
- 56 Kvetnoi IM, Levin IM (1986). Melatonin and tumor growth. (In Russian with English abstract). *Eksp Onkol.* **8**(4): 11–15.
- 57 Lachowicz-Ochedalska A, Rebas E, Kunert-Radek J (2000). Effects of somatostatin and its analogues on tyrosine kinase activity in rodent tumors. *Biol Signals Recept.* **9**(5): 255–9.
- 58 Lange TS, Singh RK, Kim KK (2007). Anti-proliferative and pro-apoptotic properties of 3-bromoacetoxy calcidiol in high-risk neuroblastoma. *Chem Biol Drug Des.* **70**(4): 302–10.
- 59 Lee LT, Schally AV, Liebow C (2008). Dephosphorylation of cancer protein by tyrosine phosphatases in response to analogs of luteinizing hormone-releasing hormone and somatostatin. *Anticancer Res.* **28**(5A): 2599–605.
- 60 Liang Y, Li QF, Zhang XY (2009). Differential expression of nuclear matrix proteins during the differentiation of human neuroblastoma SK-N-SH cells induced by retinoic acid. *J Cell Biochem.* **106**(5): 849
- 61 Lincoln DT, Sinowatz F, Temmim-Baker L, Baker HI, Kölle S, Waters MJ (1998). Growth hormone receptor expression in the nucleus and cytoplasm of normal and neoplastic cells. *Histochem Cell Biol.* **109**(2): 141–159.
- 62 Lissoni P, Rovelli F, Malugani F, Bucovec R, Conti A, Maestroni GJ (2001). Anti-angiogenic activity of melatonin in advanced cancer patients. *Neuro Endocrinol Lett.* **22**(1): 45–47.
- 63 Liu Y, Yang H, Otaka K, Takatsuki H, Sakanishi A (2005). Effects of vascular endothelial growth factor (VEGF) and chondroitin sulfate A on human monocytic THP-1 cell migration. *Colloids Surf B Biointerfaces.* **43**(3–4): 216–220.
- 64 Maestroni GJ, Hertens E, Galli P, Conti A, Pedrinis E (1996). Melatonin-induced T-helper cell hematopoietic cytokines resembling both interleukin-4 and dynorphin. *J Pineal Res.* **21**(3): 131–9.
- 65 Majewski S, Szmurlo A, Marczak M, Jablonska S, Bollag W (1994). Synergistic effect of retinoids and interferon alpha on tumor-induced angiogenesis: anti-angiogenic effect on HPV-harboring tumor-cell lines. *Int J Cancer.* **57**(1): 81–85.
- 66 Malafa MP, Fokum FD, Smith L, Louis A (2002). Inhibition of angiogenesis and promotion of melanoma dormancy by vitamin E succinate. *Ann Surg Oncol.* **9**(10): 1023–1032.
- 67 Manni A, Boucher AE, Demers LM, Harvey HA, Lipton A (1989). Simmonds MA, *et al.* Endocrine effects of combined somatostatin analog and bromocriptine therapy in women with advanced breast cancer. *Breast Cancer Res Treat.* **14**(3): 289–298.
- 68 Mantell DJ, Owens PE, Bundred NJ, Mawer EB, Canfield AE (2000). 1  $\alpha$ ,25-dihydroxyvitamin D(3) inhibits angiogenesis in vitro and in vivo. *Circ Res.* **87**(3): 214–220.

- 69 Massa A, Barbieri F, Aiello C (2004). The expression of the phosphotyrosine phosphatase DEP-1/PTPeta dictates the responsiveness of glioma cells to somatostatin inhibition of cell proliferation. *J Biol Chem.* **279**(28): 29004–12.
- 70 McMillan K, Perrepelitsyn I, Wang Z, Shapshay SM (1999). Tumor growth inhibition and regression induced by photothermal vascular targeting and angiogenesis inhibitor retinoic acid. *Cancer Lett.* **137**(1): 35–44.
- 71 McMillan CR, Sharma R, Ottenhof T (2007). Modulation of tyrosine hydroxylase expression by melatonin in human SH-SY5Y neuroblastoma cells. *Neurosci Lett.* **419**(3): 202–6.
- 72 Mediavilla MD, Cos S, Sánchez-Barceló EJ (1999). Melatonin increases p53 and p21WAF1 expression in MCF-7 human breast cancer cells in vitro. *Life Sci.* **65**(4): 415–420.
- 73 Mentlein R, Eichler O, Forstreuter F, Held-Feindt J (2001). Somatostatin inhibits the production of vascular endothelial growth factor in human glioma cells. *Int J Cancer.* **92**(4): 545–550.
- 74 Mishima M, Yano T, Jimbo H, Yano N, Morita Y, Yoshikawa H, *et al.* (1999). Inhibition of human endometrial cancer cell growth in vitro and in vivo by somatostatin analog RC-160. *Am J Obstet Gynecol.* **181**(3): 583–590.
- 75 Moertel CL, Reubi JC, Scheithauer BS (1994). Expression of somatostatin receptors in childhood neuroblastoma. *Am J Clin Pathol.* **102**(6): 752–6.
- 76 Murata A, Morishige F, Yamaguchi H (1982). Prolongation of survival times of terminal cancer patients by administration of large doses of ascorbate. *Int J Vitam Nutr Res Suppl.* **23**: 103–113.
- 77 Murray RD, Kim K, Ren SG (2004). Central and peripheral actions of somatostatin on the growth hormone-IGF-I axis. *J Clin Invest.* **114**(3): 349–56.
- 78 Neuzil J, Kagedal K, Andera L, Weber C, Brunk UT (2002). Vitamin E analogs: a new class of multiple action agents with anti-neoplastic and anti-atherogenic activity. *Apoptosis.* **7**(2): 179–87.
- 79 Norsa A, Martino V (2006). Somatostatin, retinoids, melatonin, vitamin D, bromocriptine, and cyclophosphamide in advanced non-small-cell lung cancer patients with low performance status. *Cancer Biother Radiopharm.* **21**(1): 68–73.
- 80 Norsa A, Martino V (2007). Somatostatin, retinoids, melatonin, vitamin D, bromocriptine, and cyclophosphamide in chemotherapy-pretreated patients with advanced lung adenocarcinoma and low performance status. *Cancer Biother Radiopharm.* **22**(1): 50–5.
- 81 Onogi N, Okuno M, Matsushima-Nishiwaki R, Fukutomi Y, Moriwaki H, Muto Y, *et al.* (1998). Antiproliferative effect of carotenoids on human colon cancer cells without conversion to retinoic acid. *Nutr Cancer.* **32**(1): 20–24.
- 82 Orlando C, Raggi CC, Bagnoni L (2001). Somatostatin receptor type 2 gene expression in neuroblastoma, measured by competitive RT-PCR, is related to patient survival and to somatostatin receptor imaging by indium -111-pentetreotide. *Med Pediatr Oncol.* **36**(1): 224–6.
- 83 Ozerdem U, Stallcup WB (2004). Pathological angiogenesis is reduced by targeting pericytes via the NG2 proteoglycan. *Angiogenesis.* **7**(3): 269–276.
- 84 Pawlikowski M, Lachowicz L, Kunert-Radek J (1998). Differential effects of somatostatin and its analog on protein tyrosine kinases activity in the rat pituitary and the murine colonic tumors. *Biochem Biophys Res Commun.* **246**(2): 375–7.
- 85 Peverali FA, Orioli D, Tonon L (1996). Retinoic acid-induced growth arrest and differentiation of neuroblastoma cells are counteracted by N-myc and enhanced by max overexpressions. *Oncogene.* **12**(2): 457–62.
- 86 Piedrafita FJ, Pfahl M (1997). Retinoid-induced apoptosis and Sp1 cleavage occur independently of transcription and require caspase activation. *Mol Cell Biol.* **17**(11): 6348–58.
- 87 Pinzani P, Orlando C, Raggi CC, Distanti V, Valanzano R, Tricarico C, *et al.* (2001). Type-2 somatostatin receptor mRNA levels in breast and colon cancer determined by a quantitative RT-PCR assay based on dual label fluorogenic probe and the TaqMan technology. *Regul Pept.* **99**(2–3): 79–86.
- 88 Pizarro JG, Yeste-Velasco M, Esparza JL (2008). The antiproliferative activity of melatonin in B65 rat dopaminergic neuroblastoma cells is related to the downregulation of cell cycle-related genes. *J Pineal Res.* **45**(1): 8–16.
- 89 Pollak M (1997). The potential role of somatostatin analogues in breast cancer treatment. *Yale J Biol Med.* **70**(5–6): 535–539.
- 90 Pumphrey CY, Theus AM, Li S, Parrish RS, Sanderson RD (2002). Neoglycans, carbodiimide-modified glycosaminoglycans: a new class of anticancer agents that inhibit cancer cell proliferation and induce apoptosis. *Cancer Res.* **62**(13): 3722–8.
- 91 Reardon DB, Wood SL, Brautigan DL (1996). Activation of a protein tyrosine phosphatase and inactivation of Raf-1 by somatostatin. *Biochem J.* **314** ( Pt 2): 401–4.
- 92 Sall JW, Klisovic DD, O'Dorisio MS (2004). Somatostatin inhibits IGF-1 mediated induction of VEGF in human retinal pigment epithelial cells. *Exp Eye Res.* **79**(4): 465–76
- 93 Schaer JC, Waser B, Mengod G, Reubi JC (1997). Somatostatin receptor subtypes sst1, sst2, sst3 and sst5 expression in human pituitary, gastroentero-pancreatic and mammary tumors: comparison of mRNA analysis with receptor autoradiography. *Int J Cancer.* **70**(5): 530–537.
- 94 Schally AV, Comaru-Schally AM, Nagy A, Kovacs M, Szepeshazi K, Plonowski A, *et al.* (2001). Hypothalamic hormones and cancer. *Front Neuroendocrinol.* **22**(4): 248–291.
- 95 Schally AV, Nagy A (2003). New approaches to treatment of various cancers based on cytotoxic analogs of LHRH, somatostatin and bombesin. *Life Sci.* **72**(21): 2305–20.
- 96 Sestini R, Orlando C, Peri A (1996). Quantitation of somatostatin receptor type 2 gene expression in neuroblastoma cell lines and primary tumors using competitive reverse transcription-polymerase chain reaction. *Clin Cancer Res.* **2**(10): 1757–65.
- 97 Shklar G, Schwartz JL (1996). Vitamin E inhibits experimental carcinogenesis and tumour angiogenesis. *Eur J Cancer B Oral Oncol.* **32B**(2): 114–119.
- 98 Steták A, Lankenau A, Vántus T (2001). The antitumor somatostatin analogue TT-232 induces cell cycle arrest through PKCdelta and c-Src. *Biochem Biophys Res Commun.* **285**(2): 483–8.
- 99 Stio M, Celli A, Treves C (2001). Synergistic anti-proliferative effects of vitamin D derivatives and 9-cis retinoic acid in SH-SY5Y human neuroblastoma cells. *J Steroid Biochem Mol Biol.* **77**(4–5): 213–22.
- 100 Sun L, Fuselier JA, Murphy WA (2002). Antisense peptide nucleic acids conjugated to somatostatin analogs and targeted at the n-myc oncogene display enhanced cytotoxicity to human neuroblastoma IMR32 cells expressing somatostatin receptors. *Peptides.* **23**(9): 1557–65.
- 101 Swettenham E, Witting PK, Salvatore BA, Neuzil J (2005). Alphatocopheryl succinate selectively induces apoptosis in neuroblastoma cells: potential therapy of malignancies of the nervous system? *J Neurochem.* **94**(5): 1448–56.
- 102 Szepesházi K, Halmos G, Schally AV, Arencibia JM, Groot K, Vadillo-Buenfil M, *et al.* (1999). Growth inhibition of experimental pancreatic cancers and sustained reduction in epidermal growth factor receptors during therapy with hormonal peptide analogs. *J Cancer Res Clin Oncol.* **125**(8–9): 444–452.
- 103 Tada M, Kobayashi H, Moriuchi T (1999). Molecular basis of pituitary oncogenesis. *J Neurooncol.* **45**(1): 83–96. Review.
- 104 Takada N, Isogai E, Kawamoto T, *et al.* (2001). Retinoic acid-induced apoptosis of the CHP134 neuroblastoma cell line is associated with nuclear accumulation of p53 and is rescued by the GDNF/Ret signal. *Med Pediatr Oncol.* **36**(1): 122–6.
- 105 Tang FY, Meydani M (2001). Green tea catechins and vitamin E inhibit angiogenesis of human microvascular endothelial cells through suppression of IL-8 production. *Nutr Cancer.* **41**(1–2): 119–125.
- 106 Todisco M (2006). Relapse of high-grade non-Hodgkin's lymphoma after autologous stem cell transplantation: a case successfully treated with cyclophosphamide plus somatostatin, bromocriptine, melatonin, retinoids, and ACTH. *Am J Ther.* **13**(6): 556–7.

- 107 Todisco M, Casaccia P, Rossi N (2001). Cyclophosphamide plus somatostatin, bromocriptin, retinoids, melatonin and ACTH in the treatment of low-grade non-Hodgkin's lymphomas at advanced stage: results of a phase II trial. *Cancer Biother Radiopharm.* **16**(2): 171–7.
- 108 Todisco M (2009). Chronic lymphocytic leukemia: long-lasting remission with combination of cyclophosphamide, somatostatin, bromocriptine, retinoids, melatonin, and ACTH. *Cancer Biother Radiopharm.* **24**(3): 353–5.
- 109 Turley JM, Funakoshi S, Ruscetti FW, Kasper J, Murphy WJ, Longo DL, *et al.* (1995). Growth inhibition and apoptosis of RL human B lymphoma cells by vitamin E succinate and retinoic acid: role for transforming growth factor beta. *Cell Growth Differ.* **6**(6): 655–663.
- 110 Turner HE, Nagy Z, Gatter KC, Esiri MM, Harris AL, Wass JA (2000). Angiogenesis in pituitary adenomas – relationship to endocrine function, treatment and outcome. *J Endocrinol.* **165**(2): 475–481.
- 111 Ueda K (2001). Detection of the retinoic acid-regulated genes in a RTBM1 neuroblastoma cell line using cDNA microarray. *Kurume Med J.* **48**(2): 159–64.
- 112 Van Eijck CH, Kwekkboom DJ, Krenning EP (1998). Somatostatin receptors and breast cancer. *Q J Nucl Med.* **42**(1): 18–25.
- 113 Vidal S, Oliveira MC, Kovacs K, Scheithauer BW, Lloyd R (2000). Immunolocalization of vascular endothelial growth factor in the GH3 cell line. *Cell Tissue Res.* **300**(1): 83–88.
- 114 Voigt A, Hartmann P, Zintl F (2000). Differentiation, proliferation and adhesion of human neuroblastoma cells after treatment with retinoic acid. *Cell Adhes Commun.* **7**(5): 423–440.
- 115 Watson JC, Balster DA, Gebhardt BM, O'Dorisio TM, O'Dorisio MS, Espenan GD, *et al.* (2001). Growing vascular endothelial cells express somatostatin subtype 2 receptors. *Br J Cancer.* **85**(2): 266–272.
- 116 Wiedermann CJ, Reinisch N, Braunsteiner H (1993). Stimulation of monocyte chemotaxis by human growth hormone and its deactivation by somatostatin. *Blood.* **82**(3): 954–960.
- 117 Witzigmann H, Tröbs RB (2008). All-trans retinoic acid arrests neuroblastoma cells in a dormant state. Subsequent nerve growth factor/brain-derived neurotrophic factor treatment adds modest benefit. *J Pediatr Surg.* **43**(7): 1284–94.
- 118 Wu PY, Lin YC, Chang CL (2009). Functional decreases in P2X7 receptors are associated with retinoic acid-induced neuronal differentiation of Neuro-2a neuroblastoma cells. *Cell Signal.* **21**(6): 881–91
- 119 Zeitler P, Siriwardana G (2000). Stimulation of mitogen-activated protein kinase pathway in rat somatotrophs by growth hormone-releasing hormone. *Endocrine.* **12**(3): 257–64.